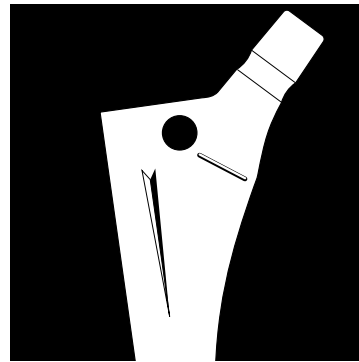
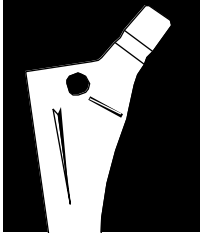




**VERSYS  
ENHANCED  
TAPER HIP  
PROSTHESIS**

**Surgical  
Technique  
for Primary Hip  
Arthroplasty**





# VERSYS ENHANCED TAPER HIP PROSTHESIS\* SURGICAL TECHNIQUE FOR PRIMARY HIP ARTHROPLASTY

## CONTENTS

### DEVELOPMENT TEAM:

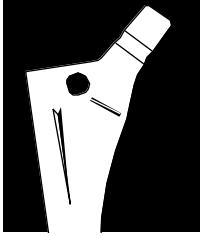
Prof. R. Giacometti Ceroni  
*Milan, Italy*  
Prof. P. Cherubino  
*Varese, Italy*  
M. Jasty, M.D.  
*Boston, MA., U.S.A.*

DESIGN PHILOSOPHY OF THE VERSYS ENHANCED TAPER HIP PROSTHESIS .....	2
PREOPERATIVE PLANNING .....	2
Determination of Leg Length.....	2
Determination of Abductor Muscle Tension ..	3
Component Size Selection/Templating .....	4
SURGICAL TECHNIQUE .....	6
Incision .....	6
Exposure of the Hip Joint .....	6
Determination of Leg Length.....	6
Osteotomy of the Femoral Neck.....	6
Preparation of the Femur .....	7
Insertion of the Femoral Component.....	10
Attachment of the Femoral Head .....	11
Wound Closure .....	12
POSTOPERATIVE MANAGEMENT .....	12

Please refer to the package insert for complete product information, including contraindications, warnings, and precautionary information.

\*U.S. Patent Pending

Various components of the VerSys Hip System are covered by one or more of the following: U.S. Patents 4,281,420; 4,336,618; 4,491,987; 4,795,472; 4,963,155; 5,013,324; 5,018,285; 5,089,003; 5,156,624; 5,192,323; 5,326,362; 5,480,453; 5,496,375/Other U.S. and foreign patents pending.



## DESIGN PHILOSOPHY

The benefits of a taper hip prosthesis are well recognized, especially in European orthopaedic communities.<sup>1,2,3</sup> The collarless design and narrow distal taper provide greater flexibility with implant sizing. This results in optimal implant seating and metaphyseal fill which, in turn, promotes proximal loading.

To appreciate the significance of this flexibility in implant sizing, it is essential to understand three important points regarding initial implant fixation and patient selection:

- 1) It has been recognized that with a press-fit tapered prosthesis, primary proximal fixation is best obtained within a structurally sound bed of cancellous bone near the cortico-cancellous junction.
- 2) Initial distal fixation is avoided to promote proximal loading.
- 3) This type of primary fixation is best achieved with younger patients who have trumpet-shaped femurs and good bone quality. Therefore, the *VerSys* Enhanced Taper Hip Prosthesis is intended for use in patients having such femoral geometry and bone characteristics.

It is also important to understand that the fixation philosophy of the taper stem is different from that of a porous non-tapered cylindrical stem. With porous non-tapered stems, the surgical goal is to aggressively fill the proximal and distal femur. However, as stated above, the proximal stem of the *VerSys* Enhanced Taper Hip

Prosthesis *should be embedded in cancellous bone* to accommodate the proximal fins on the prosthesis. These fins stand proud of the rasp envelope by 2.5mm at the highest point. It is important to understand this difference in approach, particularly if a surgeon's experience with cementless hip implants has primarily involved porous non-tapered prostheses. Failure to recognize this important distinction could lead to a fracture of the proximal femur caused by over-sizing the implant to the femur.

Because of the tapered stem shape, the *VerSys* Enhanced Taper Hip Prosthesis also can be used for CDH when narrow distal canals can be encountered.

## Preoperative Planning

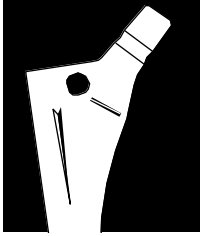
Preoperative planning provides an opportunity to see the impact of different interventions without causing irreversible changes to the patient's anatomy. Then, when the final decision on technique is made, the surgeon can have the appropriate implants available at surgery.

The key objectives of preoperative planning include:

1. Determination of leg length,
2. Establishment of appropriate abductor muscle tension, and
3. Determination of the anticipated component sizes.

## Determination of Leg Length

Determining the preoperative leg length is essential for restoration of the appropriate leg length during surgery. For most patients, leg



lengths are not equal. If, on clinical examination, both the recumbent and the standing measurements are equal, the leg length determination is simplified. If not, or if there is concern about abnormalities of the knee, foot, or ankle (such as equine deformities, or flexion or varus/valgus deformities), perform further radiographic evaluation to aid in the determination of preoperative leg length status.

An A/P pelvis radiograph often gives enough documentation of leg length inequality to proceed with surgery. If more information is needed, a scanogram or CT evaluation of leg length may be helpful. From the clinical and radiographic information on leg lengths, determine the appropriate correction, if any, to be achieved during surgery.

If the limb is to be significantly shortened, osteotomy and advancement of the greater trochanter should be considered. If the limb is shortened without osteotomy and advancement of the greater trochanter, the abductors will be lax postoperatively, and the risk of dislocation will be high. Also, gait will be compromised by the laxity of the abductors.

If leg length is to be maintained or increased, it is usually possible to perform the operation successfully without osteotomy of the greater trochanter. However, if there is some major anatomic abnormality, osteotomy of the greater trochanter may be helpful.

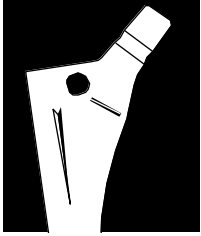
### **Determination of Appropriate Abductor Muscle Tension**

Once the requirements for establishing the desired postoperative leg length have been

decided, the next step is to consider the requirement for abductor muscle tension. When the patient has a very large offset between the center of rotation of the femoral head and a line that bisects the medullary canal, the insertion of a femoral component with a lesser offset will, in effect, medialize the femoral shaft. To the extent that this occurs, laxity in the abductors will result.

*VerSys* Enhanced Taper stems have a specific advantage in this regard. The *VerSys* stems are designed with a 135-degree neck angle. This neck angle, combined with a neck length range of 14mm, allows for a variety of offset choices. This versatility in offset and length helps eliminate the problem of having a greater offset in the normal femur than could potentially exist in the prosthesis.

Although rare, it may not be possible to restore offset in patients with an unusually large preoperative offset or with a severe varus deformity. In such cases, the tension in the abductors can be increased by lengthening the limb, a method that is especially useful when the involved hip is short. If this option is not advisable and if the disparity is great between the preoperative offset and the offset achieved at surgery by using the longest head-neck piece possible, some surgeons may choose to osteotomize and advance the greater trochanter to eliminate the slack in the abductor muscle. Others may choose to use a different type of prosthesis.



## Component Size Selection

When templating, magnification of the femur will vary depending on the distance from the x-ray source to the film, and the distance from the patient to the film. The *Versys Hip System* templates (Fig. 1) use standard 120 percent magnification, which is near the average magnification on most clinical x-rays. Large patients and obese patients may have magnification greater than 120 percent because their osseous structures are farther away from the surface of the film. Similarly, smaller patients may have magnification less than 120 percent. To better determine the magnification of any x-ray film, use a standardized marker at the level of the femur. (Templates of 115 and 110 percent magnification can be obtained by special order.)

The initial templating begins with the A/P roentgenogram.

Preoperative planning is important in choosing the optimal acetabular component, and in providing an estimation of the range of acetabular components that might ultimately be required. Assess several sizes to estimate which acetabular component will provide the best fit for maximum coverage. In most cases, select the largest component possible, being certain that the outside diameter is not too large to seat completely in the bone.

(Refer to the Zimmer *Trilogy*® Acetabular System surgical technique for further details on acetabulum reconstruction.)

Consider the position and thickness of the acetabular component in estimating the optimum femoral neck length to be used. (To simplify this, the acetabular templates are on a

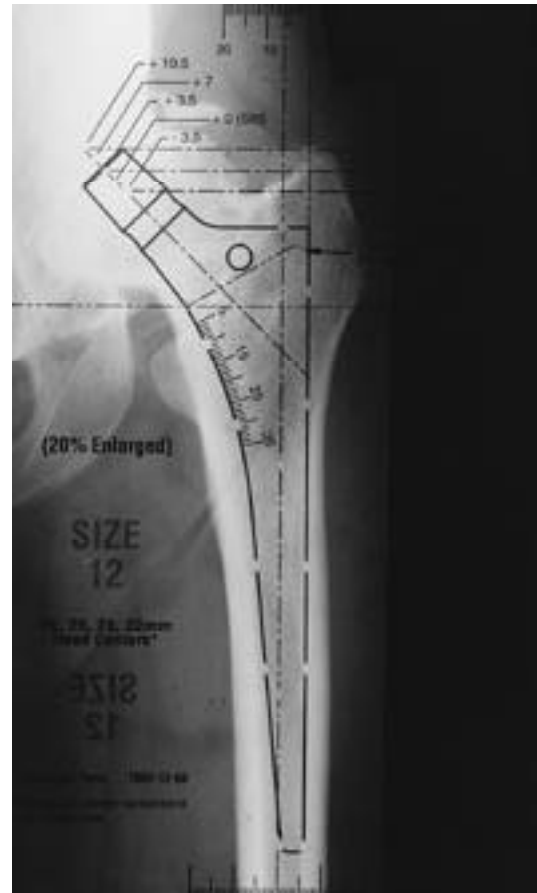
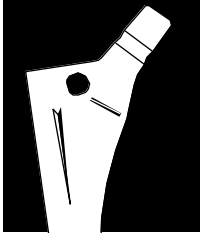


Fig. 1

transparent overlay, separate from the femoral templates.) Mark the acetabular size and position, and the center of the head on the x-rays. This allows any femoral component to be matched with the desired acetabular component by placing the femoral template over the acetabular template. This will provide the best estimation of femoral component size and head-neck length necessary to achieve the correct leg length.

The *VerSys Hip System* includes four head diameters. In most patients with average-sized acetabula, consider a femoral head with an intermediate diameter, such as 26mm or 28mm. The intermediate femoral heads allow the use of a smaller acetabular component while also



allowing for a polyethylene liner of sufficient thickness.

In special circumstances, such as the treatment of small patients, juvenile rheumatoid patients, and patients with congenital hip dysplasia and small acetabular volume, it is preferable to use a 22mm diameter head with a small acetabular component to allow for increased liner thickness.

The specific objectives in templating the femoral component include:

- 1) Determining the anticipated size of the implant to be inserted, and
- 2) Determining the height of the implant in the femur and the location of the femoral neck cut.

Begin by positioning the femoral template. Pay particular attention to the metaphyseal fill of the prosthesis. The stem should closely fill the metaphysis while avoiding distal stem contact. Leave a bed of cancellous bone (1.0mm - 2.0mm) for the fins on the stem. Try to position the stem so the medial contour parallels the contour of the medial femoral cortex.

Assess the template fit of at least three implant sizes. This templating exercise will give an approximate size to be used. The final decision should be made during implantation. In most cases, when templating reveals a size that is between two implant sizes, choose the smaller size to ensure that some cancellous bone will remain.

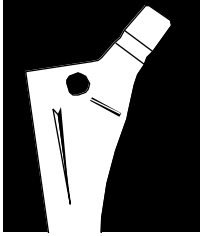
With the lateral edge of the prosthesis parallel to the axis of the femur, move the template along

the femoral stem axis to obtain stem fit and to choose the appropriate head center. Generally, if the leg length is to remain unchanged, the center of the head of the prosthesis should be at the same level as the center of the patient's femoral head. This should also correspond to the center of the templated acetabulum.

After the stem height has been determined, note the distance in millimeters from the osteotomy level on the template to the superior border of the lesser trochanter using the millimeter scale on the template.

For example, one might determine from the templating that a 52mm OD socket is probably the size to use with a size 15 prosthesis and a +3.5 x 28mm diameter head-neck piece placed 15mm above the lesser trochanter. Proximal adjustments in prosthesis position can eliminate the possible need of a femoral head with a skirt. Intraoperative osteotomy guides replicate these transparent overlay templates to help transfer these measurements to the hip during surgery. Each stem template shows the neck length and offset for each of the head-neck combinations (-3.5 to +10.5, depending on head diameter). Note that skirts are present on +7mm and +10.5mm on size 26, 28, and 32mm heads, and +3.5mm on the size 22mm head.

If these evaluations are satisfactory, check the fit of the stem on the lateral x-ray. Then, again verify proximal fill, taking special note of the anterior cortex distal to the lesser trochanter in addition to any excessive anterior bow to the femur that may prevent implant seating.



## SURGICAL TECHNIQUE

### **Incision**

In total hip arthroplasty, exposure can be achieved through a variety of methods. The most common method is a posterolateral approach.

Following the posterolateral approach of Kocker-Langenbeck, position the patient on the operating table in the true lateral position. This position must be accurately determined and firmly held since the orientation of the acetabular component will relate to this position. Flex the bottom hip and knee approximately 45 degrees with the leg well padded and secured to the table. Prepare the skin in the usual way and drape the lower extremity. Center the incision over the posterior aspect of the greater trochanter and extend it distally paralleling the femur for about four inches. Angle the proximal portion of the incision posteriorly and superiorly at 45 degrees in the direction of the posterior inferior iliac spine and continue it approximately four inches in this direction from the trochanter. The incision can be extended in either direction depending on the unique requirement of each operation.

Divide the fascia lata in line with the skin incision through the full length of the wound. Begin this division of the fascia lata at the distal end of the incision, particularly if there has been previous surgery in the area of the hip. Identification of the tissue planes is easiest at the distal end of the wound.

### **Exposure of the Hip Joint**

Develop the exposure of the posterior capsule. To facilitate this, place the leg in internal

rotation. The key landmark for division of the short external rotators is the tendon of the piriformis muscle. This tendon runs parallel to the posterior border of the gluteus medius and can be readily palpated as it approaches the posterior superior portion of the greater trochanter. Retract the gluteus medius superiorly and identify the tendon of the piriformis.

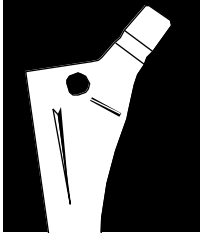
### **Determination of Leg Length**

Establish landmarks and obtain measurements before dislocation of the hip so that, after reconstruction, a comparison of leg length and femoral shaft offset can be obtained. From this comparison, adjustments can be made to achieve the goals established during preoperative planning. There are several methods to measure leg length. One method is to fix a leg length caliper to the wing of the ilium. Then, take baseline measurements to a cautery mark at the base of the greater trochanter while marking the position of the lower limb on the table.

### **Osteotomy of the Femoral Neck**

It is important to avoid inserting the femoral component in a varus position. This error can usually be avoided by improving visualization of the posterior femoral neck. To accomplish this, remove all of the remaining soft tissue on the posterior femoral neck, exposing the intertrochanteric crest and the junction between the femoral neck and greater trochanter. Release the inferior capsule to expose the lesser trochanter.

When the ideal position of the selected femoral component was determined during preoperative planning, the distance between the top surface of the lesser trochanter and the osteotomy level was noted. In the example used, this measure-



ment was 15mm. Use this information now to determine the level for the femoral neck osteotomy.

With the hip dislocated in internal rotation and the tibia perpendicular to the femur with the foot toward the ceiling, expose the proximal portion of the femur. Superimpose the *VerSys* Osteotomy Guide (Fig. 2) on the femur. This guide is a metal replica of the template. There are two criteria for positioning the guide. First, determine the varus or valgus relationship so that the center line of the femoral stem overlays the diaphyseal midline, bisecting the longitudinal axis of the medullary canal. Then palpate both the medial and lateral cortices of the femur in the region of the isthmus through the bulk of the vastus lateralis muscle group.

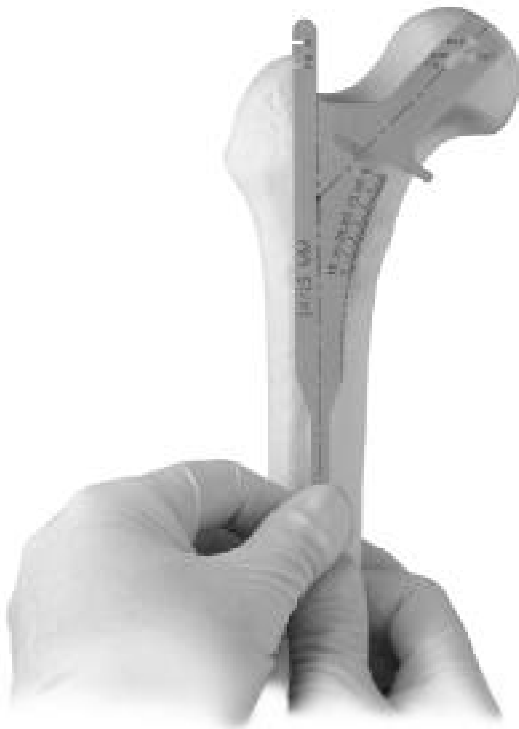

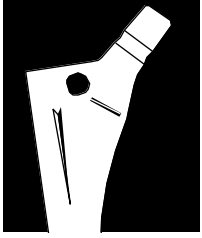
Fig. 2

Once varus or valgus alignment has been determined, move the Osteotomy Guide proximally or distally to the correct height. The determination of how far proximal or distal to move this guide is made based on preoperative planning. The *VerSys* Osteotomy Guides have a linear scale starting at the collar and running distally along the medial edge. This scale is identical to that used preoperatively on the acrylic template. Since the desired position, in the example used, of the height of the femoral component is 15mm proximal to the top of the lesser trochanter, adjust the template proximally and distally until that relationship has been established. At that point, use electrocautery to inscribe a line across the femoral neck parallel to the undersurface of the Osteotomy Guide.

Using the inscribed line as a guide, perform the osteotomy of the femoral neck. To prevent possible damage to the greater trochanter, stop the cut as the saw approaches the greater trochanter. Remove the saw and either bring it in from the superior portion of the femoral neck to complete the osteotomy cut, or use an Osteotome to finish the cut.

### **Preparation of the Femur**

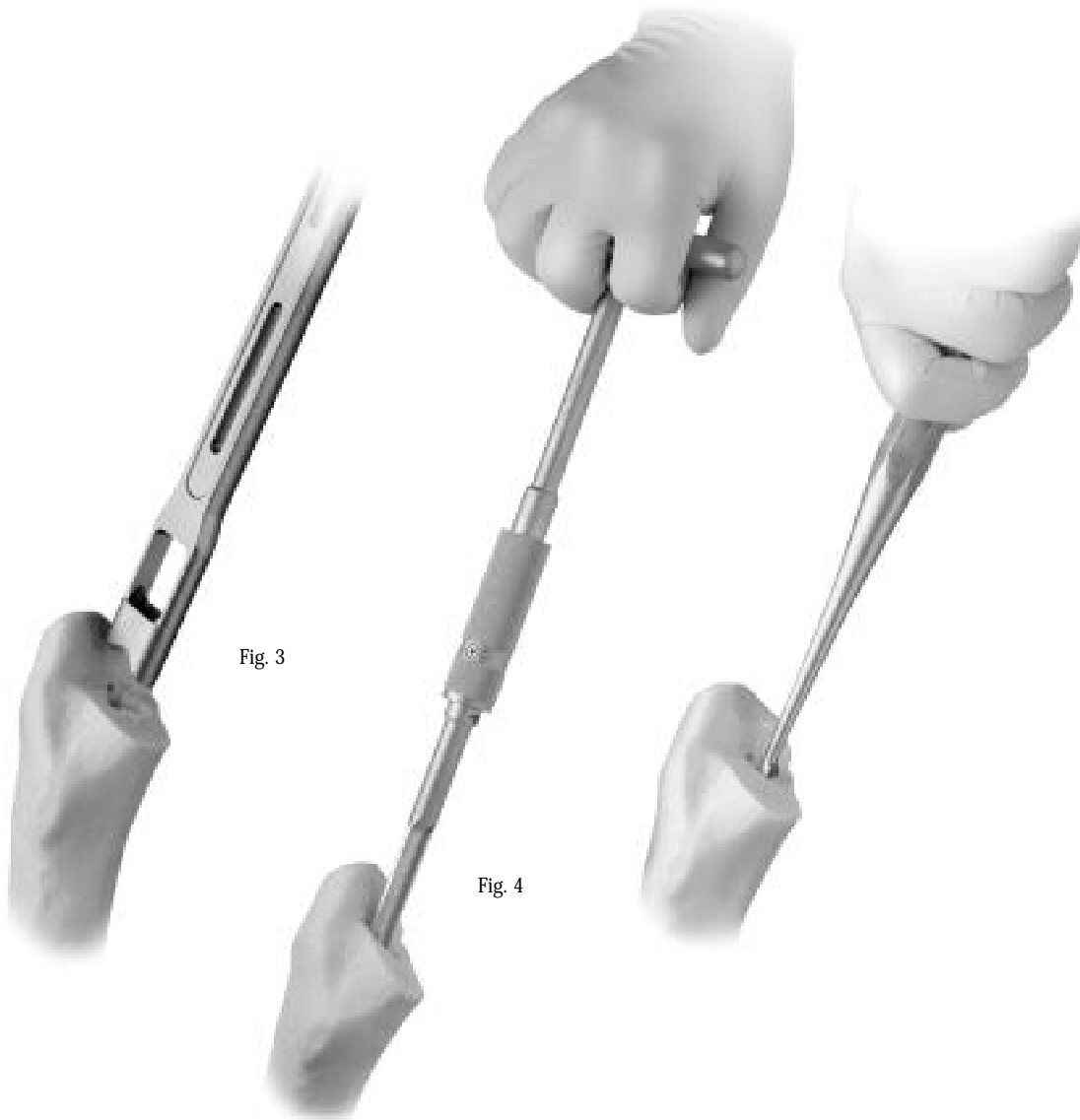
To appropriately insert the femoral prosthesis, excellent exposure of the proximal femur must be obtained. The femur should extend out of the wound, and soft tissue should be removed from the medial portion of the greater trochanter and lateral portion of the femoral neck. It is crucial to adequately visualize this area so the correct

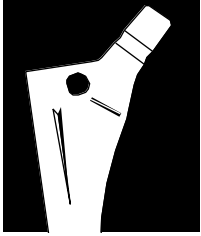


insertion site for femoral reaming can be located. Refer to the preoperative planning at this point. Identify the mid-femoral shaft extension intraoperatively as viewed on the A/P and lateral radiographs. This is usually in the area of the piriformis tendon insertion in the junction between the medial trochanter and lateral femoral neck. Use the Box Osteotome (Fig. 3) to remove this medial portion of the greater trochanter and lateral femoral neck. The opening must be large enough for the passage of each

sequential rasp to ensure neutral rasp/implant alignment. An insufficient opening may result in varus stem positioning. Before using the next size rasp, be sure that the opening is large enough. If it is not, use the Box Osteotome again. After using the Box Osteotome, insert the Tapered Awl or Curette (Figs. 4 and 5) to open the medullary canal. This will provide a reference for the direction of femoral rasping.

To align the rasp, insert the *VerSys* Alignment Rod (Fig. 6) into the proximal hole of the rasp.





Then reference the Alignment Rod with the lower leg to verify that the rasp has appropriate anteversion.

Begin femoral rasping (Fig. 7) with a rasp 2 or 3 sizes smaller than the anticipated prosthesis size. If the broach is easily inserted and adequate cancellous bone in the metaphyseal region is available, remove the first rasp and insert the next size rasp. Be certain that the rasp advances with each blow of the mallet. If it is difficult to insert the rasp, do not advance to the next larger size rasp. It is very important that the rasping procedure does not remove all of the proximal

cancellous bone. The press-fit of the implant's self-cutting proximal fins should be accomplished with a 1-2mm bed of cancellous bone to account for the proximal fins on the implant, which are proud of the rasp envelope by 2.5mm at the highest point on every stem size. These fins will self-cut into the cancellous bone and nick the cortical bone. However, they should not be driven into cortical bone, or fracture of the femur may result.

With the final rasp inserted to the proper level, assemble the Provisional Head Neck Taper (Fig. 8) and perform a trial reduction. Adjust the neck length to achieve the appropriate leg length and femoral offset. It is important at this stage to reposition the leg exactly where it was during the

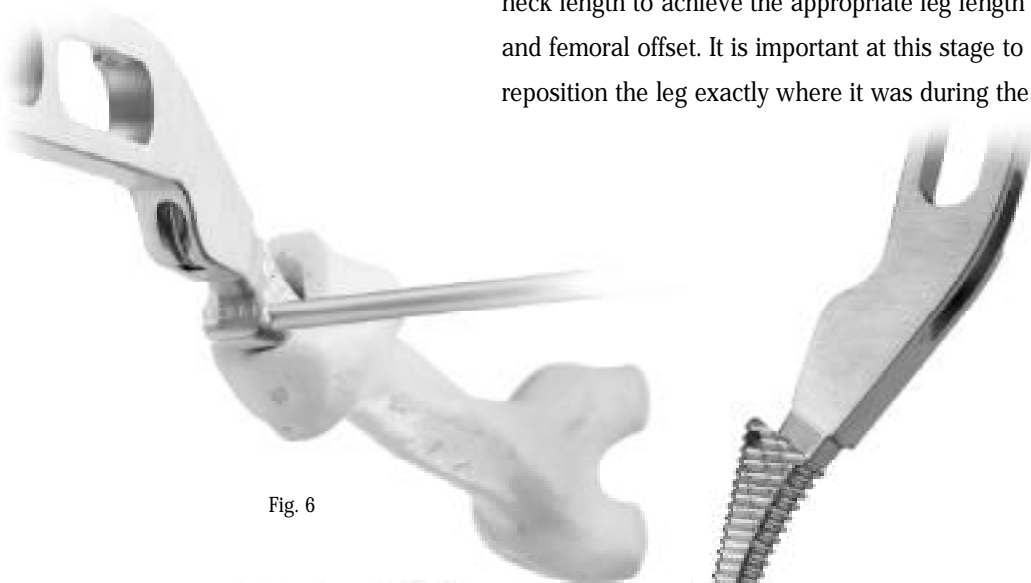


Fig. 6

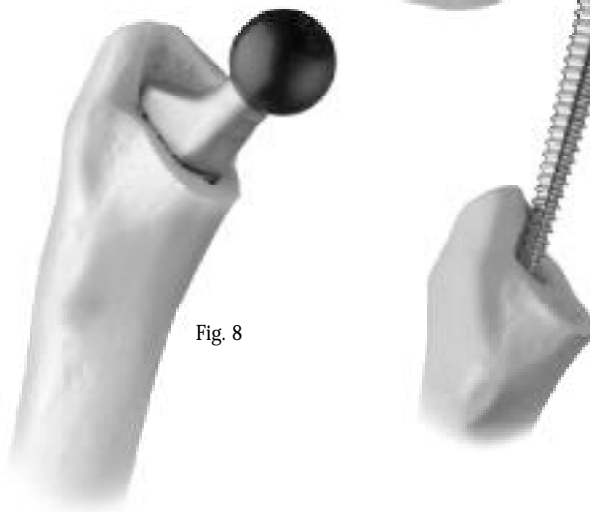
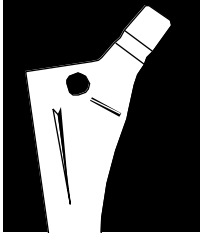


Fig. 8



first measurement.

Remove the Provisional Head Neck Taper. Using electrocautery, mark the femur at the point of intersection of the calcar mid-line and the medial calcar (Fig. 9). When this guide mark has been established, remove the rasp.

### Insertion of the Femoral Component

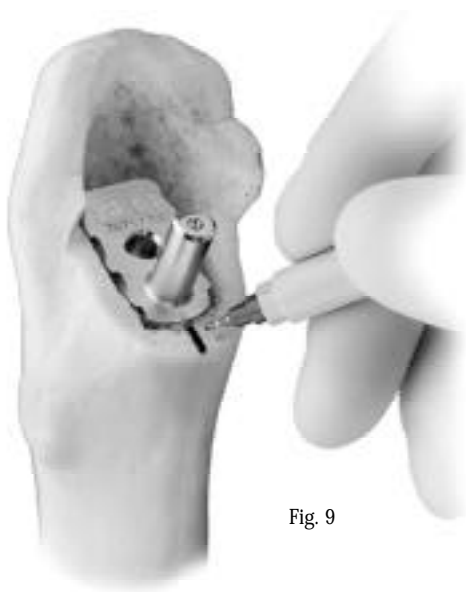


Fig. 9

Begin to insert the femoral prosthesis by hand, pushing lightly until minimal resistance is felt. Be sure to position the implant laterally (Fig. 10 and 10a) before the proximal fins on the implant engage. Seat the implant first with hand pressure. Then, attach the Rotation Alignment Guide (Fig. 11) to the implant and verify the rotation of the stem within the canal before further impacting the stem. Now fit the *VerSys* Driver (Fig. 12) to the implant insertion slot located on the stem shoulder. While impacting, continue to align the stem to match the mid-line previously marked on the calcar. It is very important to control rotation of the stem during insertion. Tap the handle of the Stem Impactor in a lateral direction until the prosthesis is fully seated. At that point, the osteotomy groove on the implant should be even

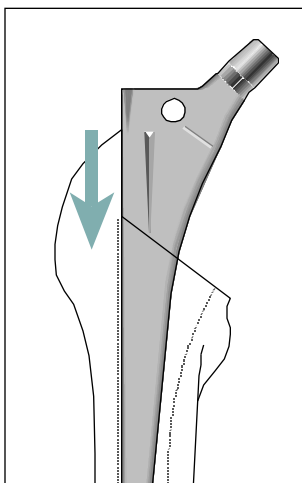


Fig. 10

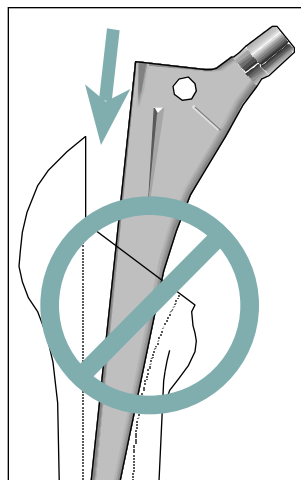
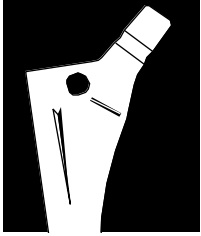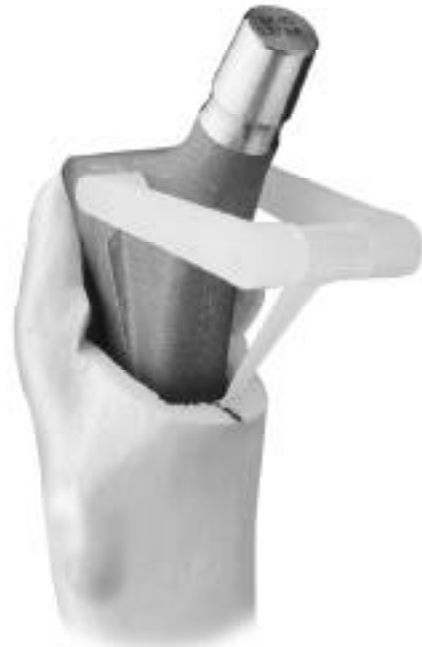


Fig. 10a





with the osteotomy of the femoral neck. The stem must advance with each blow of the mallet. If it does not, do not continue the insertion. Again, it is important to insert the implant in the exact orientation of the rasp since the fins on the proximal stem will cut through cancellous bone to provide a positive anti-rotational lock. Thus once these fins lock onto bone, adjusting the orientation will not be possible.

### **Attachment of the Femoral Head**

Do not impact the Femoral Head onto the taper before driving in the prosthesis as the Femoral Head will usually come off the stem. When the stem is fully inserted, check to ensure that the

12/14 taper is clean and dry. A provisional Femoral Head may then be used (Fig. 13) to confirm neck length selection with a trial reduction. Then place the selected femoral head (Fig. 14) on the taper and secure it firmly by twisting it and striking it two times with the Head Impactor. Test the security of the head fixation by trying to remove the head by hand. If the head must be removed after impaction, use the mallet and stem driver to carefully disengage the head from the taper by striking underneath the head.



Fig. 12

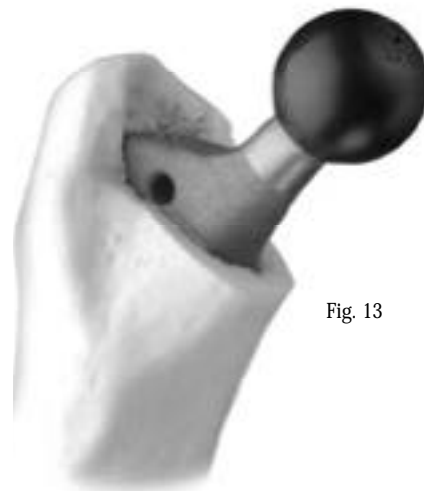
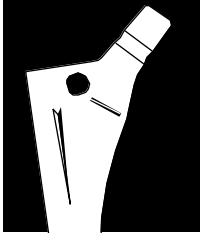


Fig. 13

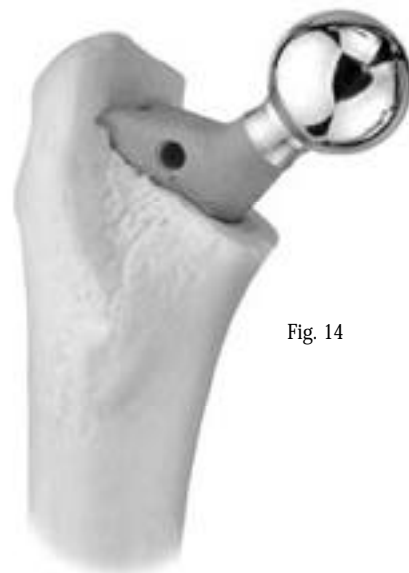

Fig. 14



Reduce the hip, and assess leg length, range of motion, stability and abductor tension for the final time.

### **Wound Closure**

After obtaining hemostasis, insert a *Hemovac*<sup>®</sup> Wound Drainage Reinfusion Device and close the wound in layers.

### **POSTOPERATIVE MANAGEMENT**

The postoperative management of patients with *VerSys* Enhanced Taper implants is very similar to that of patients with cemented total hip replacements except for the duration of crutch support. In addition, postoperative management must be emphasized to help ensure bone remodeling.

Begin joint mobilization on the first day after surgery. Partial weight-bearing is recommended

after two or three days and should continue for a duration of three months. After three months, activities should progress toward full weight-bearing. Patients who have revision surgery may be slower in reaching these goals.

Bone ingrowth patients are usually 50 percent weight-bearing on two crutches for six weeks with reduction in external support over the next six to eight weeks. Patients should be walking freely in approximately three months as the strength of the reconstruction permits walking without limp or pain. If extensive bone grafting is required for the femur or acetabulum, more prolonged crutch support is needed until the grafts have healed.

1. Giacometti RC, Pace A. CLS femoral component. *Orthopedics*. 1989;12(9): 1195-1200.
2. Spotorno L, Romagnoli S, Ivaldo N, et al. The CLS system theoretical concept and results. *Acta Orthopaedica Belgica*. 1993;59(1): 144-148.
3. Robinson RP, Lovell TP, Green TM. Hip arthroplasty using the cementless CLS stem. *J Arthroplasty*. 1994;9(2): 177-192.

